Case Series

Musculoskeletal Ultrasound – The Physiatrists and Third Eye

Kumar Raj[1], KB Sumalatha[2], Mittal Nimish[3], Handa Gita[4], Singh U[5]

Abstract

The Department of PMR, AIIMS, New Delhi started using musculoskeletal ultrasound (US) 6 years back in 2009. The department has performed over 1615 US diagnostic examinations and more than 523 US guided interventions in last 20 months (from Nov 2013 to June 2015). Most of the diagnostic examination done on shoulder (n=762) followed by ankle (n=216), knee (n=173), Hip (n=170), elbow and forearm (n=158), wrist and hand (n=136). US guided interventions include joint, muscle, tenosynovitis, nerve blocks, bursae, ganglion, botulinum toxin injections etc. The current case series (six cases), 3 each of upper and lower limb demonstrates the fact that how availability of point of care ultrasound has helped in management of patients in PMR. This paper highlights the change in management of patients after performing outpatients clinic based ultrasound as it is very useful in diagnosis and intervention in musculoskeletal disorders. Ultrasound also helps in better patient education regarding the structural and dynamic impairment related to disease while doing the ultrasound itself and results in high patient satisfaction.

Key words: **Musculoskeletal ultrasound, management.**

Introduction:

The role of musculoskeletal ultrasound (MSK US) as a tool for investigating various diseases is not new in medicine. The use of diagnostic ultrasound in musculoskeletal system was adopted in Europe much before its use in the United States of America and other parts of the world. The use of musculoskeletal ultrasound in Physical Medicine and Rehabilitation (PMR) started picking up in last few decades. It is a useful adjunct to routine history and examination of the musculoskeletal system and adds third dimension to what we inspect, palpate, percuss and measure during the clinical examination. This additional advantage provided by ultrasound helps in confirmation of diagnosis, prevents unnecessary costly investigations, helps in better musculoskeletal training of medical students, makes them understand the value of surface marking and anatomy during clinical examination and helps in targeting better interventional physiatric procedures. Apart from the above advantages, another important factor is the high patient satisfaction seen while using the point of care musculoskeletal ultrasound.

Despite the availability of the technology, the only obstacle in MSK US use is the operator dependence to the extent that it's been said that "A fool with a stethoscope will be a fool with an ultrasound machine". The same analogy applies to the use of MSK US. Currently, no mentorship programmes exist in physical medicine and rehabilitation for MSK US and the only source of training is the MSK US workshops being arranged by the various academies and societies. Hence, the learning curve is steep and initial self-learning on oneself and normal volunteers along with cadaveric dissection and online image repositories is used.

The Department of PMR at our tertiary care centre started using MSK US 6 years ago. Initial phase was difficult and a lot of patience, persistence and devoted time went in to understand the machine and the anatomy as displayed in the image repositories. Since then, the department has come a long way. We have performed over 1615 MSK US diagnostic examinations and more than 523 US guided interventions in last 20 months (from Nov 2013 to June 2015) . Most of the diagnostic examination were done on shoulder (n =

Authors' affiliation:

[1] *MBBS, MD, PGDGM, (PMR), Assistant Professor*
[2] *MBBS, D, PGDGM, (PMR), Assistant Professor*
[3] *MBBS, MD, Clinical Fellow*
[4] *MBBS, MD, (PMR), Professor*
[5] *MBBS, DPMR, DNB (PMR), Professor*

Deptt. of PMR, *AIIMS, New Delhi- 110041*

Cite as:

Kumar Raj, KB Sumalatha, Mittal Nimish, Handa Gita, Singh U, Musculoskeletal Ultrasound – The Physiatrist's and Third Eye, March 2017; Vol 28 (1) : 31-38

Correspondence:

Dr Raj Kumar, (MBBS, MD), Assistant Professor (PMR), Department of Orthopaedics, IMS, BHU, Varanasi. Mobile - 8130160557, 8004285433, E mail: drkrraj@gmail.com.

Received on 11/12/2015, Accepted on, 07/02/2017

762) followed by ankle (n = 216), knee (n =173), hip (n =170), elbow and forearm (n =158), wrist and hand (n =136). Majority of US guided interventions included joint, muscle, peritendon areas, nerve blocks, bursa, ganglion, botulinum toxin injections etc.

While it is straightforward that the target is precisely reached under real time guidance in US imaging, there is still a debate about the usefulness and additional favourable impact of image guidance for patient treatment outcomes. The current case series highlights the advantage offered by skilful ultrasound in musculoskeletal condition diagnosis and the necessary changes in treatment protocols which translates into better patient outcomes and higher physiatrists' satisfaction.

The case studies are presented along with the discussion for the sake of conciseness and easy understanding

Case Study 1 :

History and Examination: A 33-year female, known case of rheumatoid arthritis on DMARD's presented with dull aching pain in right upper limb along with tingling and numbness of palmar aspect of hand. Initial rheumatology consult suspected cervical radiculopathy and carpal tunnel syndrome (CTS) due to mixed signs and inconclusive picture. There the patient was put on neuropathic pain medications (pregabalin 75mg twice daily) along with CTS splint. On reporting minimal relief after four weeks of therapy, patient was referred to PMR OPD.

Electrodiagnostic examination was advised after clinical examination. However, due to ease of office based availability of ultrasound in PMR a scan of the affected wrist was performed. US findings included a ganglion resting superomedial to flexor pollicis longus tendon, superior to index finger flexor tendon and adjacent to the median nerve. On complete extension of all fingers, the ganglion tunnelled inside the carpal tunnel and compressed the median nerve. Beautiful visualisation of findings was seen on dynamic US examination keeping the probe on distal radius, proximal carpal bones and doing alternate finger flexion and extension manoeuvre. The diagnosis of CTS was later confirmed by electrophysiological study (EPS).

MSK US Findings:

Carpal tunnel ganglion: Image at distal forearm (just proximal to wrist crease) showing ganglion (green), sitting above flexor tendon of index and middle finger

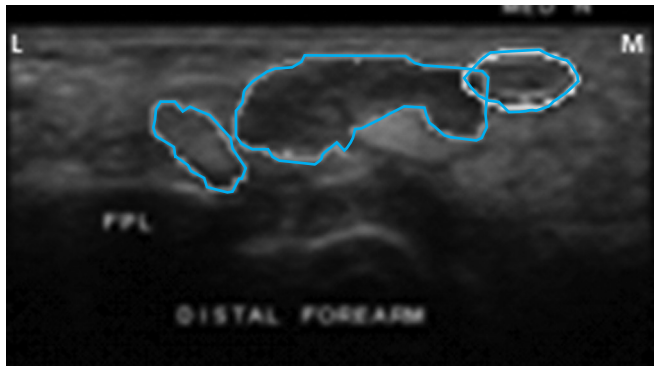

Fig 1a- Carpal Tunnel Ganglion: Image at Distal Forearm (Just Proximal to Wrist Crease) Showing Ganglion (Green), Sitting above Flexor Tendon of Index and Middle Finger Displacing Median Nerve (Yellow) Medially. Flexor Pollicis Longus (FPL) is Shown as Obliquely Oval Hyperechoic Structure (Blue). L-Lateral, M-Medial

Fig 1b- Carpal Tunnel Ganglion: Similar Image as of Fig1a with Markings

displacing median nerve (yellow) medially. Flexor pollicis longus (FPL) is shown as obliquely oval hyperechoic structure (blue) (Figs 1a & 1b).

MSK US Advantage

1) Early office based diagnosis
2) Confirmation of aetiology by dynamic examination
3) Precise location of ganglion with subsequent aspiration

Discussion: The EPS report of the patient showed increased right median nerve distal sensory (6.8ms) and motor latency (6.9ms) and decreased sensory conduction velocity (18). Ganglia are not so common soft tissue tumours in the wrist and compression of peripheral nerves by ganglia is unusual and only a few cases have been reported in the literature[1,2]. Earlier case reports of CTS evaluated by magnetic resonance

images have revealed an intra tunnel ganglion . In our case compression of median nerve by ganglion was a process visualised only on dynamic evaluation by high resolution MSK US, which would have not been possible with MRI. CTS splint (wrist hand orthosis in neutral position) was aggravating the pain as ganglion was tunnelling in the carpal tunnel on extension of fingers causing more compression. Benefits of MSK US in this case include office based early diagnosis, cost saving with no requirement of MRI and guided intervention not possible with MRI.

Case Study 2:

History and Examination: A 29-year right handed female housewife presented with history of insidious onset, gradually progressive deformity in right hand for last 2 months. On examination, we noticed partial clawing of right hand (ring and little fingers) and altered sensation in ulnar distribution but found no skin lesion anywhere in the body. B/L ulnar nerve were non-tender, not thickened with negative tinel sign at elbow. Mild swelling was noted on ulnar side of mid forearm which was hard to quantify as mild asymmetry of forearm thickness is usual in right handed persons.

MSK US of ulnar nerve at elbow and forearm was done which revealed a small hypoechoic cyst in middle part of flexor carpi ulnaris compressing the ulnar nerve. Thus structutal cause for partial hand clawing was found and treated accordingly.

MSK US findings:

Muscular cysticercosis: Forearm showing circular hypoechoic cyst with central hyperechoic part representing scolex (Fig 2a).

Muscular Cysticercosis: A cyst (circular hypoechoic

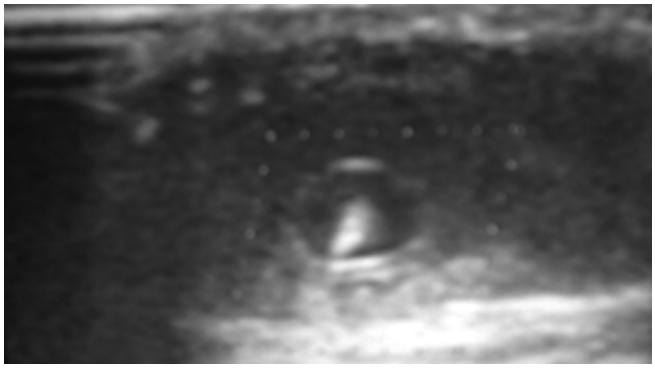

Fig 2a- Muscular Cysticercosis: Forearm Showing Circular Hypoechoic Cyst with Central Hyperechoic Part Representing Scolex of Cysticercosis

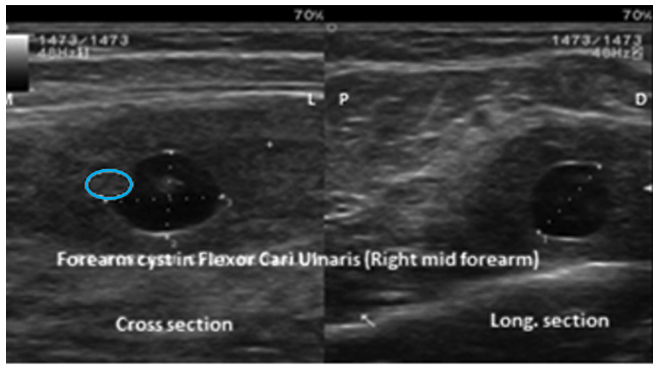

Fig 2b - Muscular Cysticercosis: A Cyst (Circular Hypoechoic Region) With Scolex (Inside Hyperechoic Dot Like Structure) in Flexor Carpi Ulnaris at Right Mid Forearm Level. Ulnar Nerve (Marked Yellow) Is Seen Just Adjacent to the Cyst.M-Medial, L-Lateral, P-Proximal, D-Distal.

region) with scolex (inside hyperechoic dot like structure) in flexor carpi ulnaris at right mid forearm level. Ulnar nerve (marked yellow) is seen just adjacent to the cyst (Fig 2b).

MSK US Advantage:

1) Early office based diagnosis of a structural lesion causing ulnar nerve compression.

2) Low cost burden to patient.

3) Prevention of inappropriate costly investigations as idiopathic ulnar nerve palsy and patient would have undergone numerous tests.

Management with USG –Structural compression of ulnar nerve, managed with albendazole 400 mg twice daily for 15 days and relief of symptoms.

Discussion: In the forearm, 3 distinct types of muscular cysticercosis have been described: the myalgic type; the mass like type, pseudotumour type, or abscess like type; and the rare pseudo hypertrophic type[3,4]. However, most cases of muscular and subcutaneous cysticercosis are asymptomatic[5,6]. Cysticercosis usually appears as an oval or round well-defined cystic lesion with an eccentric echogenic scolex in it. In our patient it was a bit central. For symptomatic solitary cysts outside the central nervous system, generally surgical resection is advocated. Ecysted larvae do not always result in clinical symptoms (as in this case main symptom was partial clawing of hand). For multiple or multilocular cyst or where surgery cannot be done, systemic therapy with antihelmintic drugs such as praziquantel and albendazole is advocated [7-9].

Case Study 3 :

History and Examination: A 72-year-old female came with pain and stiffness of right shoulder for 6 weeks. Pain was insidious in onset, with no history of trauma. No present or past history was suggestive of diabetes or rheumatologic condition. On examination, patient had mild to moderate restriction in shoulder abduction, flexion and external rotation suggestive of adhesive capsulitis of shoulder.

MSK US findings: Complete tear of right supraspinatus tendon with retracted tendon showing "naked tuberosity sign" (Fig 3a). On comparison with normal left side, we were surprised to visualize findings suggestive of supraspinatus tendinosis (thickening with mixed echogenicity both hypo and hyper) with small insertional bursal tear and intraarticular tear (Fig 3b).

Fig 3a- Complete Supraspinatus Tear with Naked Tuberosity Sign: Symptomatic Shoulder (Right) Showing Supraspinatus Tear With Retraction of Fibres and Naked Tuberosity

Supraspinatus tear: Asymptomatic side (left) showing supraspinatus tear (bursal side and intra-articular side)

Fig 3b- Supraspinatus Tear: Asymptomatic Side (Left) Showing Supraspinatus Tear (Bursal Side and Intra Articular Side)

with naked tuberosity sign: Symptomatic shoulder (right) showing supraspinatus tear with retraction of fibres and naked tuberosity.

Management before MSK US: Patients was being managed as primary adhesive capsulitis of shoulder, with no relief in symptoms.

Management after MSK US: Considering that the left shoulder was completely asymptomatic, it didn't require any treatment other than preventive measures. We discussed the option of referring her for surgical repair of the right side but she was unwilling for any surgery considering her age and wanted to try conservative options. We prescribed a home based physical therapy programme focusing on isometric strengthening of shoulder abductors and rotators with a handout for preventive strategies' and movements to avoid. The value of MSK US in this case lies in early prediction of aetiology for adhesive capsulitis which subsequently resulted in change of the treatment protocol.

MSK US advantage: Formulation of conservative treatment protocol in accordance with aetiology for adhesive capsulitis resulting in better patient treatment outcome.

Discussion: This study enlightens the importance of clinical correlation with imaging modalities for proper management of the patient and how MSK US helps in patient education regarding one's condition. Diagnostic ultrasound is an excellent modality to incorporate into the overall evaluation of the musculoskeletal conditions of shoulder. Current options for this evaluation include arthrogram, CT arthrogram, MRI (with or without arthrogram), and ultrasonography .In a previous meta-analysis, De Jesus *et al*[10] compared and summarised the diagnostic accuracy of MRI and ultrasonography for rotator cuff tears. USG has sensitivity and specificity of 92.3% and 94.9% respectively for full thickness tear, 66.7 %and 93.5% respectively for partial thickness tears, 90.4% and 92% for overall tear, while MRI has sensitivity and specificity of 92.1 and 92.9 respectively for full thickness tear, 63.6 and 91.7 respectively for partial thickness tear, 85.5 and 85.1 for overall tear .

Case Study 4:

History and Examination: A 30 -years old, overweight female presented with insidious onset, dull achy, constant lower backache of around one year duration, radiating to left buttocks and occasionally to the left thigh. Activity made it worse and sometimes even rolling in bed resulted in severe pain. She had visited

multiple physicians including orthopedicians and neurologists but nothing specific was diagnosed and she was managed as degenerative disc disease secondary to old disc herniation. Her examination revealed pain in both flexion as well as extension. Straight leg raising test on left was 60º and that on right was 80º with no neurological deficit. We noticed a small nodular swelling just below her left posterosuperior iliac spine (PSIS) region which she mentioned as the single most tender point. X-ray sacroiliac joint (SIJ) was normal

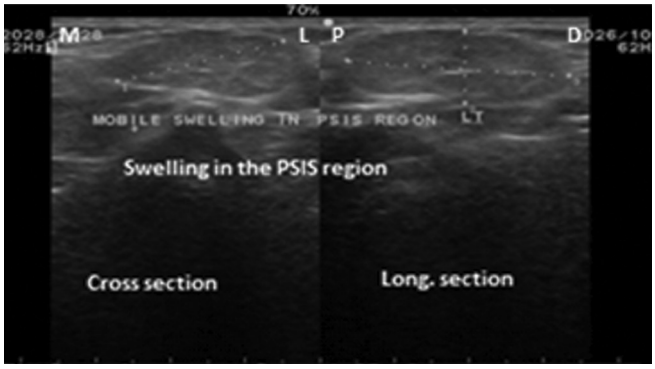

Fig 4- Episacral Lipoma: Showing as Isoechoic Oval Mass over Posterior Superior Iliac Spine Region

and x-ray and MRI LS spine showed findings consistent with degenerative disc and degenerative joint disease. With additional findings suggestive of posterocentral disc protrusions at L5-S1 level.

MSK US findings: An oval, well localised, homogenous echoic mass (most likely episacral lipoma) with no flow on color Doppler, sitting above left sacroiliac joint measuring 2.9×2.3×1.2 cm.

Episacral lipoma: showing as isoechoic oval mass over Posterior Superior iliac spine region (Fig 4).

Management before MSK US –Patient was managed as a case of disc herniation on neuropathic medication, exercises, and heat modalities with mild relief. She also received epidural caudal steroid injection and continuing exercises but had only minimal relief.

Management after MSK US – Infiltration of steroid and local anaesthetic provided significant relief in patient's overall conditions. After that, her compliance with conservative treatment (medications and exercises) greatly improved with near total subsidence of pain.

Discussion: Episacral lipoma (commonly called black mouse or herniated fat pad) is a treatable cause of either acute and chronic low back pain or lumbosacral radiculopathy as already described in literature for last 60-70 years. The usual aetiology is tears in the thoracodorsal fascia and subsequent herniation of a portion of the underlying dorsal fat pad through the tear. Medication and physical therapy may not be effective. Local injection of the nodule with a solution of anaesthetic and steroid is effective in treating the episacral lipoma pain for several months (18months) . We also managed our patient accordingly and patient reported complete resolution of her symptoms. The patient remained pain-free till the last follow-up six months after the injection.

Case Study 5:

History and Examination: A 38 years old female with complaints of non-traumatic right knee pain of 6 months duration, with heaviness and difficuty in walking for long distance reported in the OPD. On clinical examination, no abnormal swelling of the anterior and posterior knee region including suprapatellar and popliteal area, no joint line tenderness, no crepitation, no increase in temperature, and no tests suggestive of pathological ligamentous laxity. X-ray of bilateral knees was unremarkable. Blood investigations ruled out any primary or secondary arthritic conditions like rheumatoid arthrits or systemic lupus erthematous etc. Patient was diagnosed with early knee degenerative osteo-arthritis with patellofemoral pain symptoms and was already on collagen sachets and quadriceps strengthening exercises. She also took sessions of physical modalities but reported no relief.

MSK US findings: A hypoechoic mass was detected between medial gastrocnemius and semimembranosus with no flow in colour Doppler, communicating with posterior joint recess (many times difficult to demonstrate) diagnostic of Baker's cyst (Figs 5a and 5b). No other abnormality in knee muscles, patellar tendon, collateral ligaments, menisci and suprapatellar pouch was noticed.

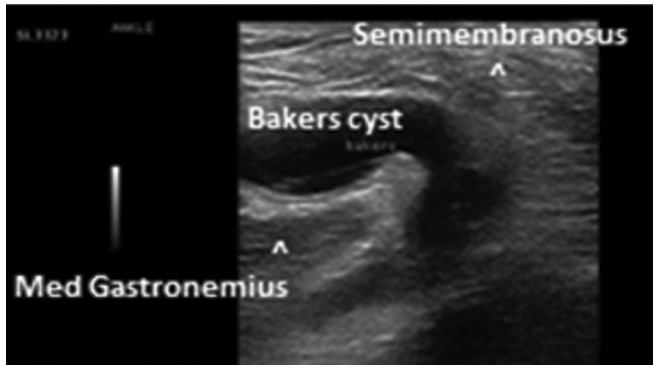

Fig 5a- Baker's Cyst in Cross Section: Hypechoic Lesion Lying between Medial Head of Gastronemius and Semi - Membranosus.

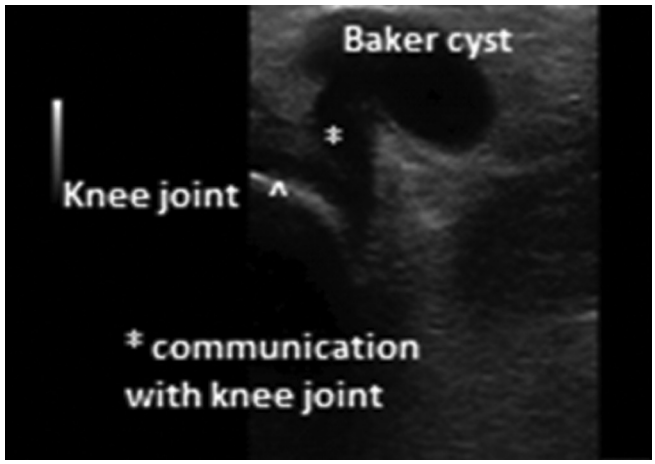

Fig 5b- Baker's Cyst Showing Communication with Knee Joint

Baker's cyst in cross section: Hypechoic lesion lying between medial head of gastronemius and semimembranosus.

Baker's cyst showing communication with knee joint.

Management before USG: Early degenerative knee osteo-arthritis with patellofemoral pain managed with conservative treatment, with minimal relief in symptoms

MSK US advantage: Diagnosis of actual patients structural location and size of baker's cyst. Therapeutic aspiration of 17 ml fluid under real time USG guidance with complete relief of symptoms. Here one may confidently say MSK USG is easy, cheap, reliable and dynamic assessment which helped not only in OPD diagnosis but also in instant treatment.Thus in single OPD visit provided both diagnosis and definitive management.

Discussion: Communication between the posterior knee joint and the medial gastrocnemius- semimembranosus bursa has been shown to increase with age, possibly because of degenerative thinning of the joint capsule and internal micro-derangements. The gastrocnemius - semimembranosus bursa is a composite of two bursae. The subgastrocnemius bursa between the medial gastrocnemius tendon and medial femoral condyle is the point of communication with the posterior joint capsule. The posterior extension of a Baker's cyst represents the second bursa between the medial gastrocnemius tendon and semimembranosus tendon that commonly communicates with the subgastrocnemius bursa. In a study by Ward *et al*[11] they compared Baker's cysts in MRI and USG and found that 59% anechoic, 23% hypoechoic, and 18% showed mixed echogenicity relative to muscle in ultrasound. Anechoic cystic structure was associated with 100% specificity and 100% positive predictive value in the diagnosis of Baker's cyst *versus* any other mass.

Case Study 6:

History and Examination: An 8 years child with spastic quadriparetic cerebral palsy presented with complaints of constant throbbing pain in posterior thigh, with mild swelling and redness of the region. No history suggestive of inciting traumatic event was present. On detailed history, the child reported initiation of pain after undergoing routine physical therapy at school. On examination there was noticable diffuse swelling of back of thigh raising the suspicion of hamstring strain.

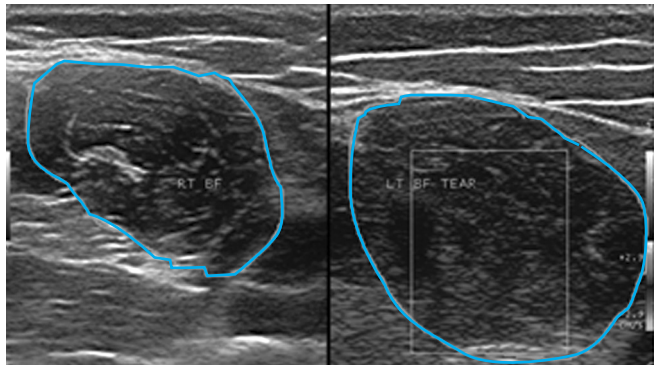

Fig 6a- Biceps Femoris Muscle: In Cross Section Showing Normal (Left) and Right Image Showings Overall Decreased Echogenicity with Hypoechoic Area (Fluid/Haematoma) Suggestive of Partial Tear

MSK US findings: Suggestive of acute muscle tear in proximal part of both medial and lateral hamstrings. Additionaly, complete tear of tendon of adductor longus with hypoechoic fluid(?blood) and retracted distal fibres were visualised.

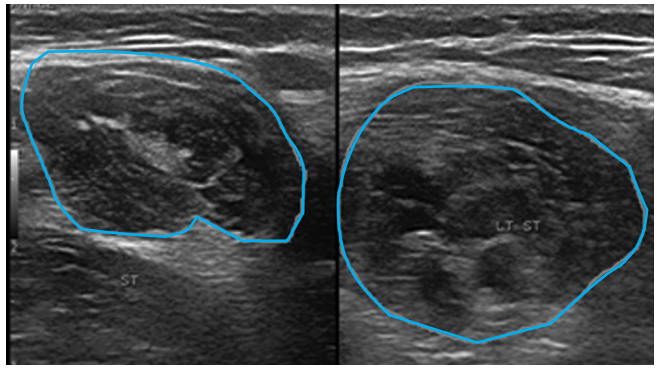

Fig 6b- Semitendinosus Muscle: In Cross Section Showing Normal (Left) and Partial Tear (Right Image)

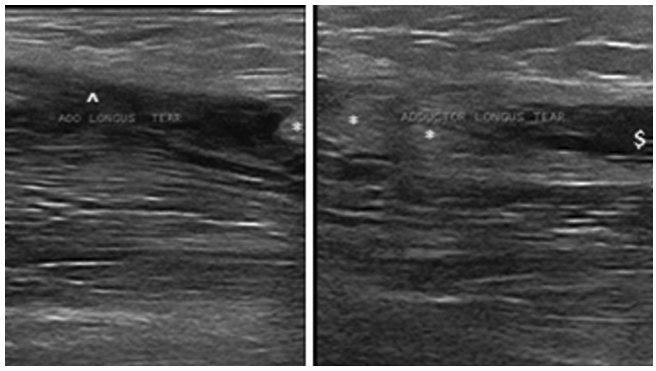

Fig 6c- Adductor Longus Tear: In Longitudinal Section ^Hypogenic Area Showing Tear *Retracted and Fibrosed Fibres of Adductor Longus $ Normal Adductor Longus Distally

Biceps femoris muscle (Fig 6a): In cross section showing normal (left) and right image showings overall decreased echogenicity with hypoechoic area (fluid/ haematoma) suggestive of partial tear.

Semitendinosus muscle (Fig 6b): In cross section showing normal (left) and partial tear (right image).

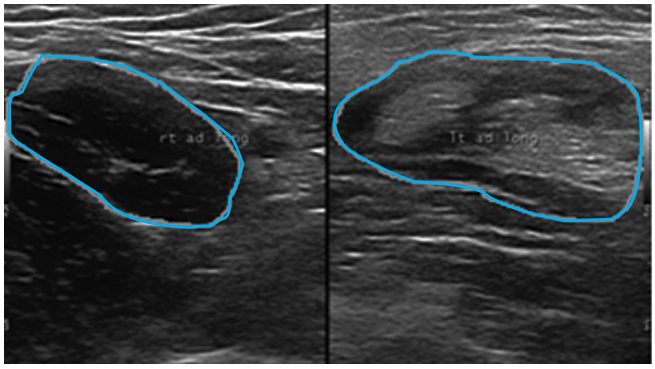

Fig 6d- Adductor Longus Tear: In Cross Section Showing Normal Side and Abnormal Side with Retracted Fibres (Right Image).

Adductor longus tear: In longitudinal section hypogenic area showing tear *retracted and fibrosed fibres of adductor longus $ normal adductor longus distally (Fig 6c).

Adductor longus tear (Fig 6d): In cross section showing normal side and abnormal side with retracted fibres (right image).

Management before MSK US: Differential diagnosis - Cellulitis, heterotropic ossification, deep vein thrombosis.

Management after MSK US: Complete rest for child with a brace and PRICE therapy. Gradual restart of gentle ROM and strengthening started after 8 weeks of rest.

Discussion: MR imaging is valuable when the global assessment of a joint requires evaluation of the muscles, tendons, cartilage, and bone marrow. Ultrasound, however, can produce similar results when a focused evaluation of muscle, tendon, and joint recesses is needed. MSK US can be used more frequently at a lower cost and with less delay when compared with MR imaging. Dynamic imaging is very helpful when differentiating full-thickness from partial-thickness tendon tears because tendon retraction indicates full-thickness tear. Although MRI is regarded as the gold standard , ultrasound examination enables identification of typical lesions of muscle strains: discontinuity of tertiary bundles, reactive oedema and haematoma. Ultrasound done after 48–72 hours reveals the evolution of the haematoma and the extent of the area affected . In cases of complete tears of the muscle belly, the retracted muscle bundles have the typical ultrasound appearance of a bell clapper surrounded by a hypoechoic haematoma . Recently Chen *et al*[12] also advocated the use of ultrasound for diagnosing adductor tears . Ultrasound as useful as MRI in depicting acute hamstring injuries and, because of lower costs, may be the preferred imaging technique .

Conclusions:

To summarise, we may conclude that MSK US guided interventions have a significant place and impact on future physical medicine and rehabilitation practice. The integration of point of care ultrasound into routine clinical practice helps in more efficient diagnosis and management in day to day practice. This case series depicts the value of MSK US in diagnosis and management of various musculoskeletal conditions in the routine OPDs and avoidance of extra cost due to time and money consuming added investigations like MRI etc. Further there is the added advantage of taking clinical management decisions in a timely manner at an office based setting. This saves a lot of time, money and energy of the patient and the physiatrist. Further, explaining to the patient during the scan makes him feel involved and helps in building doctor patient repertoire and high level of patient trust and satisfaction. Hence MSK US appears to be more cost effective and resource productive method of management.

However, the only limiting fact in its full exploitation is the steep learning curve and the pursuance of learning newer skills as it is evident that the musculoskeletal system is varied and the appearance in US is more dependent on understanding of anatomy at a particular site and does not follow a standard appearance. Further to this is the fact that there are limited learning avenues for the skill development and upgradation in MSK US in the field of physiatry. Till now, there was very limited interest in MSK US in radiologists as it was considered very low tech and less rewarding and time consuming learning process. Its integration into daily routine practice of physiatry by the next generation of practising physiatrists shall be helpful in making it more acceptable and useful mode of management. This needs to be followed up with continuing CMEs and online learning tools for constant updation of knowledge and skills. Last but not least, further analysis concerning their value and patient outcomes need to be established and validated.

References:

1. Chen CH, Wu T, Sun JS, Lin WH, Unusual causes of carpal tunnel syndrome: space occupying lesions, *J Hand Surg* 2012; **37:**14-9.
2. Kerrigan, JJ, Bertoni, JM, Jaeger SH. Ganglion cysts and carpal tunnel syndrome. *J Hand Surg* 1988; **13:** 763-5.
3. Scully R, Mark E, Mcneely W, Mcneely B. A 20-year-old Philippine woman with a soft-tissue mass in the forearm. *N Engl J Med* 1994; **330:** 1887-93.
4. Chopra JS, Nand N, Jain K. Generalized muscular pseudohypertrophy in cysticercosis. *Postgrad Med J* 1911. Schmidt DKT, Jordaan HF, Schneider JW. Cerebraland subcutaneous cysticercosis treated with albendazole. *Int J Dermatol* 1995; **34:** 574-9.
5. Schmidt DKT, Jordaan HF, Schneider JW. Cerebral and subcutaneous cysticercosis treated with albendazole. *Int J Dermatol* 1995; **34:** 574-9.
6. Yamashita P, Kelsey J, Henderson SO. Subcutaneous cysticercosis. *J Emerg Med* 1998; **16:** 583-6.
7. Brown WJ, Voge M. Cysticercosis: a modern day plague. *Pediatr Clin North Am*1985; **32:** 953-69.
8. Garcia HH, Gonzalez AE, Evans CA, Gilman RH. Cysticercosis Working Group in Peru. Taenia solium cysticercosis. *Lancet* 2003; **362:** 547-56.
9. Ogilvie CM, Kasten P, Rovinsky D, Workman KL, Johnston JO. Cysticercosis of the triceps -an unusual pseudotumor: case report and review. *Clin Orthop Relat Res* 2001; **382:** 217-21.
10. De Jesus JO, Parker L, Frangos AJ, Nazarian LN. Accuracy of MRI, MR arthrography, and ultrasound in the diagnosis of rotator cuff tears: a meta-analysis. *AJR*, 2009; **192:** 1701-7.
11. Ward EE, Jacobson JA, Fessell DP, Hayes CW, Holsbeeck MV. Sonographic detection of Baker's cysts. *AJR Am J Roentgenol* 2001; **176:** 373-80.
12. Chen DJ, Caldera FE, Kim W. Diagnosing adductor muscle avulsion at the symphysis pubis with ultrasound. *Am J Phys Med Rehabil* 2014 ; **93:** 346-8.