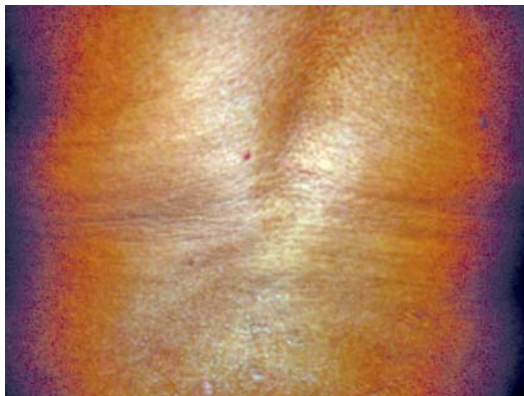
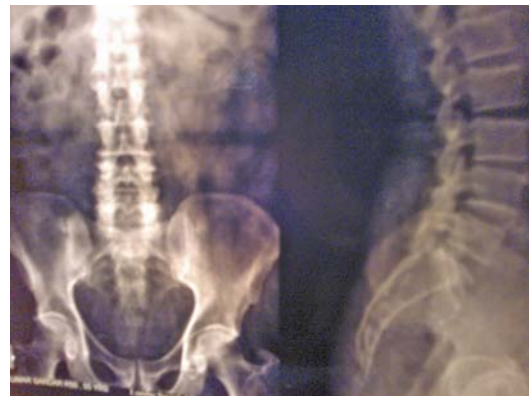

## REHAB CHALLENGES

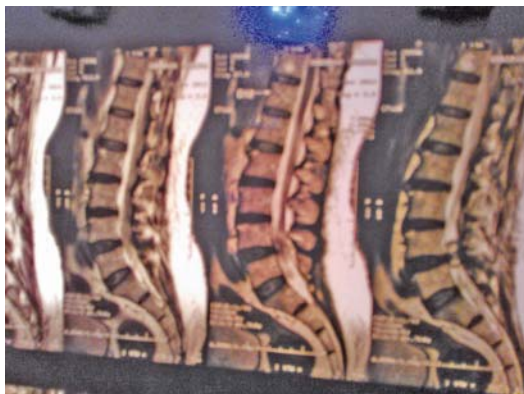A fifty years old male presented in PMR OPD with severe low back pain for last ten days. The pain was non-inflammatory in nature and radiating to right lower limb incapacitating his life. There was significant muscle spasm (Fig 1). He was treated with analgesics, muscle relaxant, heat therapy and TENS. Unfortunately he was still in agony with pain radiating to back of the thigh only. X-ray (Fig 2) of his spine showed facet joint arthropathy. MRI scan (Figs 3 & 4) showed that a cyst possible linked with facet joint. Please opine regarding the next plan of management including interventional pain approach for this particular patient.



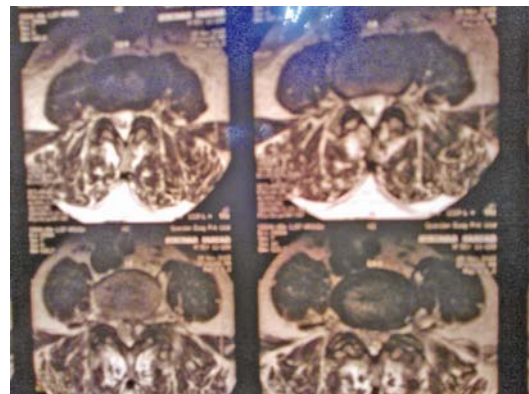
**Fig 1-** Muscle Spasm



**Fig 2-** X-ray Spine



**Fig 3-** MRI Scan



**Fig 4-** MRI Scan