A referred case of AVN of femoral head for rehabilitation

*A K Palit**

- A 40 years old male from Bangladesh presented in PMR OPD with chief complains of pain around the left hip and left groin for 4-5 years along with difficulty in walking.
- X-ray presented to the OPD

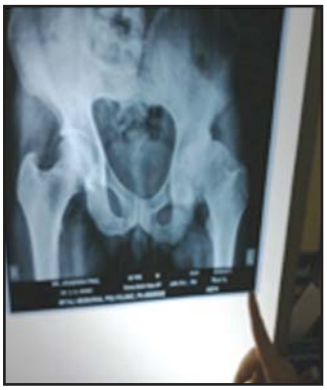

Patient is a maker of earthen idols. Normally he does most of his profession in squatting position. He noticed gradual development of pain in left groin and difficulty in rising up from the ground.After closed questionaries' an interesting history was revealed that since childhood patient noticed shortness of structures on right side of the body. Right upper limb more prominently shorter than lower limb .Now he cannot squat or sit cross-legged properly resulting in restriction of his occupation.Patient feels difficulty in right upper limb after working for some time. He didn't complain about any respiratory distress or chest pain.

General survey

Fig. 1

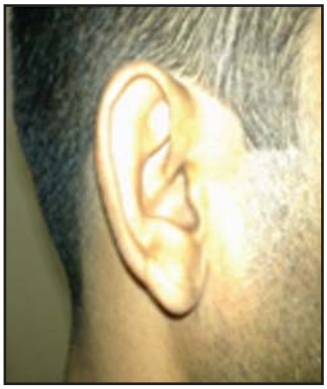

Fig. 2

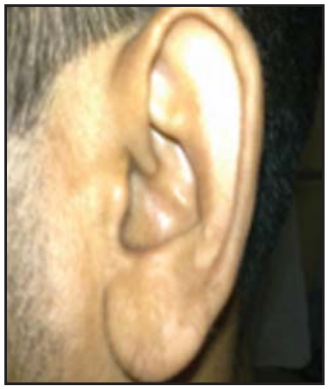

Fig. 3

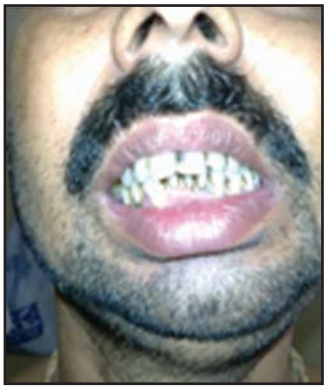

Fig. 4

It was seen that right ear smaller ½ cm. than left with hypoplastic right mandible. Interestingly it was noticed that lower incisors are receding may be due to mandibular pathology (Figs 1 to 4)

* Associate Professor PMR, IPGME&R Kolkata.

On further examination of trunk:

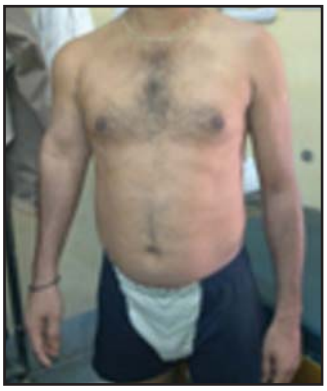
Fig. 5

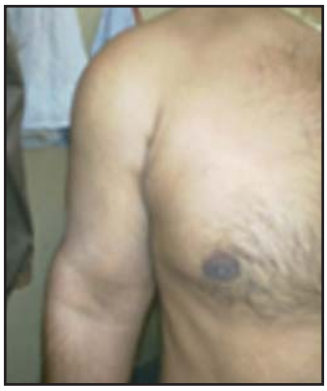
Fig. 6

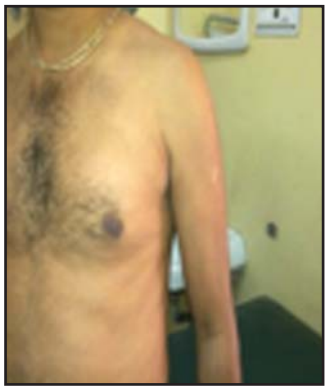
Fig. 7

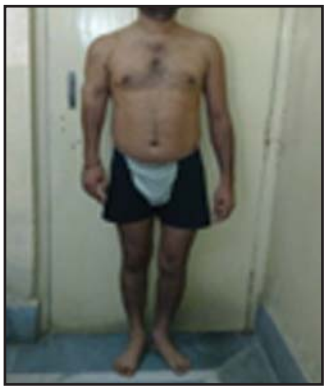
Fig. 8

Examination :

Right arm (acromion to lateral epicondyle) length was 20 cm which was much shorter than left (27cm), (Figs 5 to 8), On further inspection of lower half of body:

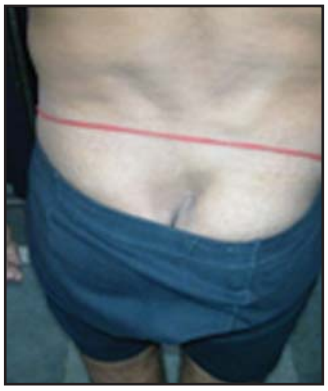
Fig. 9

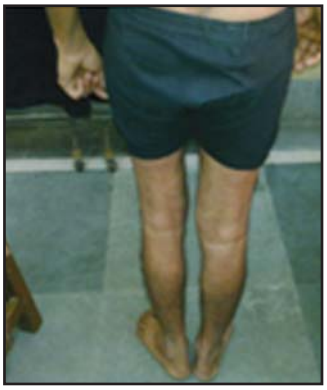
Fig. 10

Here we noticed that sacral dimple was less prominent on right side without any definite scoliosis. Right lower limb was slightly healthier than left (Figs 9 & 10). Apparently pelvic obliquity was seen (? due to smallness of sacrum on one side). There was neither any limb length discrepancy nor any neurodeficit in lower limbs. But left hip ROM was grossly restricted in all directions including a fixed flexion deformity of 10-15 degrees (by Thomas's test). Squatting and cross-legged sitting not possible and patient had an antalgic gait pattern.

X -ray : It was noticeable that sacrum on right side is smaller with obscured right sacro-iliac joint and scoliosis in lumbosacral spine .MRI of pelvis and hip showed irregularity of femoral head likely to be AVN (Figs 11 to 12)

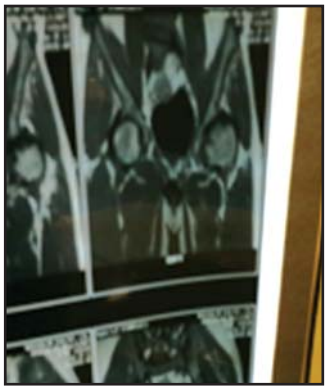
Fig. 11

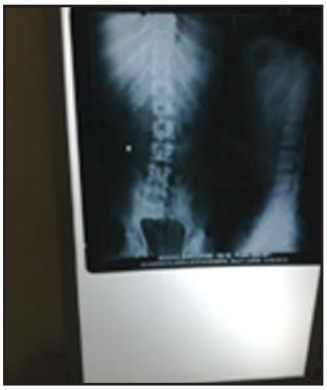
Fig. 12

All the biochemical parameters were normal and no evidences of tuberculosis were present. Patient was put on active/assistive ROM of left hip and isometric strengthening exercise of hip abductor and extensor along with hip abduction orthosis. Opinion from readers about their experience regarding any association between hemi atrophy and AVN.

REHAB CHALLENGES

A young male of 27 years working as a garage mechanic complains of chronic low back pain for more than 5 years which aggravated recently after lifting heavy weight. The pain is localised to the right side of lower back which is radiated upto the back of mid-thigh .The pain aggravates on extension, lateral bending and rotation. While straightening from bend position to erect posture he feels a sharp catch and he also complained of similar pain at night while turning in the bed along with disturbance of sleep and loss of work due to pain.

On examination there were no neurological abnormality. There is a tender point on palpation at the paraspinal area at the right side in L4/5 level. X-ray showed slight grade 1 spondylolisthesis at L4/5 level. He had an MRI done which revealed disc prolapse at L3 / L4, L4 / 5, L5 / s1.Electrodiagnostic study and other biochemical markers were normal.

The patient was put on NSAIDs, muscle relaxant and antidepressants .He was also on lumbosacral brace and static spinal exercise regimen. After 48 hours treatment of conservative regimen, theVAS score of pain was 7 and he was unable to perform his normal ADL.

Opinion from reader regarding intervention of choice for his rehabilitation at this juncture.

NB : Please send the opinion to the editor with your name, address of communication. The right responder will be acknowledged in next issue of journal.