

Heterotopic Ossification at Unusual Site in Traumatic Brain Injury

Dr Maheswarappa BM, MBBS, MD(PMR), Senior Resident, DPNR, NIMHANS, Bangalore

Dr Nair KPS, MBBS, MD(Medicine) DM (Neurology),
Associate Professor, DPNR, NIMHANS, Bangalore

Dr Taly AB, MBBS, MD (Medicine) DM (Neurology),
Professor, Dept. of Neurology, NIMHANS, Bangalore

Dr Shanthi S, MBBS, Junior Resident, DPNR, NIMHANS, Bangalore

Dr Murali T, MBBS, MD (Psychiatry), Addl. Prof and Head, DPNR NIMHANS, Bangalore

Abstract

Heterotopic ossification(HO) is a common complication among patients with spinal cord and head injury. Common sites in traumatic brain injury(TBI) are hip, shoulder and elbow joints. In the hip joints it is commonly observed around anterior, inferomedial and posterior aspect.

A six year old girl sustained head injury following a fall from the height and underwent emergency decompressive craniotomy and duraplasty. There was no evidence of injury to thigh muscles. She was referred for rehabilitation after one month of treatment at intensive care unit . Child was noted to have diffuse swelling of both thigh extending from hip to knee, and severe restriction of range of motion at both the knee joints.

Initial blood investigation showed ESR of 80 mm1st hour and elevated alkaline phosphatase of 601U/L and follow up investigation of decrease in ESR to 3mm 1st hour and alkaline phosphates 461U/L at 4 months. After 14 months ESR was 4mm and alkaline phosphates was 171U/L. Child was given indomethacin 25 mg thrice daily, gentle range of motion exercises and proper positioning of extremities. Range of motion at both knees completely recovered.

Initial X-ray showed early extensive ossification at middle third of both thighs, In the follow up X-ray done after 14 months there was significant maturation of HO and osteoporosis. Heterotopic ossification can rarely develop away from the joints in patients with TBI.

Key Words : Heterotopic ossification, Traumatic Brain Injury, Range of Motion (ROM)

Introduction:

Heterotypic Ossification(HO) is the formation of mature lamellar bone in soft tissues. It is indistinguishable histologically from normal bone. HO does not grow out of bone, is not connected to periosteum and is not formed intra-articularly. Incidence of HO in TBI ranges

from 3 to 20 percent and preferred sites are hip, shoulder and elbow joints. In the hip joints it is commonly found around anterior, inferomedial and posterior aspect¹. Since HO occurs around the joint, involvement of middle third of thighs is very unusual. Review literature and Medline search did not find HO involving middle third of both thighs in TBI. Hence we would like to report a case of unusual presentation of HO at middle third of both thighs following TBI.

Address of correspondence: Dr. Maheswarappa BM Senior Resident, Department of Psychiatric and Neurological Rehabilitation, NIMHANS, Bangalore Phone Number: 08026995281 (O) Email: maheshbm12@rediffmail.com

Case Report:

A six year girl sustained head injury following a fall and underwent emergency decompressive craniotomy and duraplasty. Her Glasgow Coma Scale (GCS) was three and there were no features of spinal injury, polytrauma, fracture of femur and evidence of injury to thighs. She was kept in intensive care unit for 60 days and no intramuscular injection was given to thighs. She was referred for rehabilitation after one month of initial care. On examination she had cognitive dysfunction, aphasia, and hypertonia of all the four limbs. After a month, child had diffuse swelling of both thigh extending from hip to knee, and severe restriction of range of motion at both

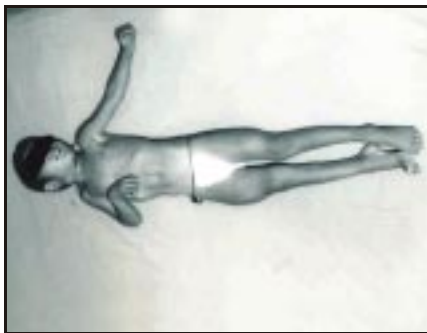

Fig.1 Swelling both thighs extending from hip to knee and knee flexion was 15 degree

the knee joints (fig1 and 2). Knee flexion was possible to only 15 degree from neutral position both side. Investigations revealed an ESR of 80 mm during 1st hour and alkaline phosphatase of 601U/L (n = 130 IU). X-ray showed early HO in the middle one third of anterior aspect of both thighs. She was given indomethacin 25 mg thrice daily, gentle range of motion exercises and proper positioning of extremities. She remained in vegetative stage for two months and cognitive function did not improve. Follow up investigations showed decrease in ESR to 3mm during 1st hour (Chart 1) and alkaline phosphatase of 461U/L at 4 months and a further decrease in alkaline

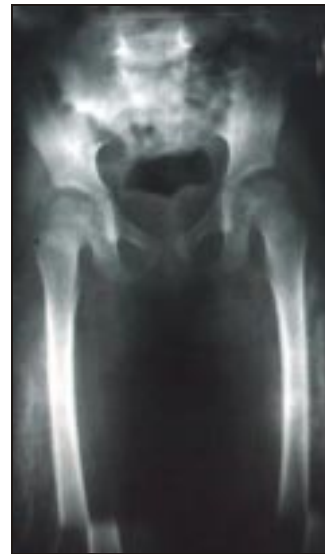

Fig.2 X-ray Shows HO of Middle one third of both thighs

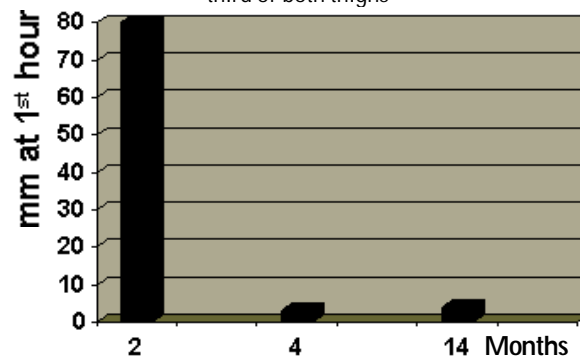


Chart 1: ESR

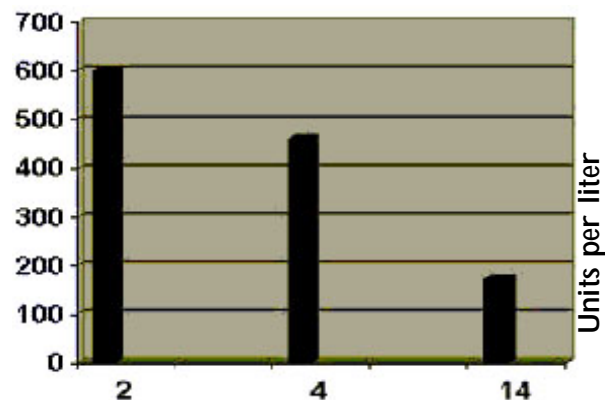


Chart 2: Alkaline phosphatase

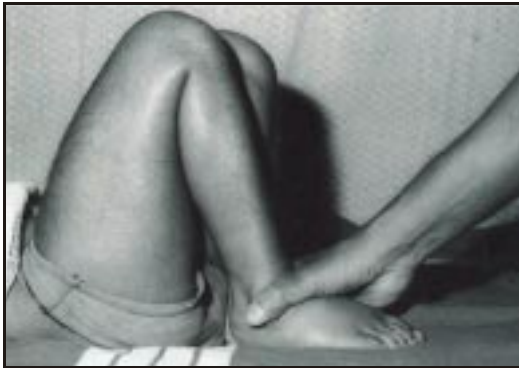

Fig.3 Marked retution of thigh Swelling and full flexion of both knee 14 months after follow-up

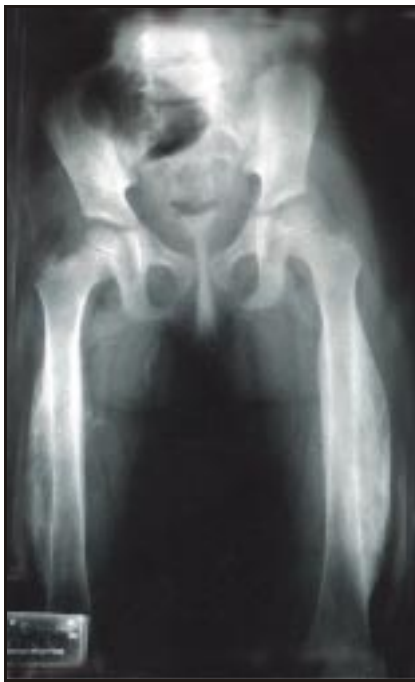

Fig. 4 X-ray Shows Significant maturation of HO and osteoporosis of both femur 14 months

phosphatase 171U/L after 14 months (chart 2). Thigh swelling decreased significantly and range of motion at both knees completely recovered. X-ray revealed significant maturation of HO at middle third of both thigh and osteoporosis of femur after 14 month (fig3 and 4).

Discussion

HO is a potential sequaele of spinal and head injury. The exact triggering mechanism for the formation of HO is unknown, but local, systemic neural, and humoral causes have been suggested. There is either a migration of distant mesenchymal cells to the area involved, with subsequent transformation of these cells into osteoblasts, or a transformation of the local mesenchymal cells directly into osteoblasts². Neurogenic heterotopic ossification is seen after any neurologic insult, notably after spinal cord injury (SPI), traumatic head injury and rarely following stroke and non traumatic spinal cord injury (NTSCI). In a prospective study conducted at National Institute of Mental Health and Neuro Sciences (NIMHANS) showed seven (6.04%) among the 114 subjects with NTSCI had HO³.

The clinical, radiological and bone scan features of HO are characteristic. Clinically pain is the most common symptom followed by decreased range of motion, localized soft tissue swelling, joint erythema and warmth, joint effusion, increasing spasticity, and low grade fever^{4,5}. Our patient had severe restriction of the ROM of knee joints and swelling. Absence of pain could be due to severe cognitive impairment. Earliest detection of HO is by three-phase bone scan but plain. Plain X-ray films are helpful in assessing the extent and shape of HO (Fig2 and 4). Spontaneous regression of HO is rare. It can cause mechanical obstruction to the joint or form bony bridges across the affected joint, resulting in ankylosis.

Gentle passive ROM at joints without stretching is cornerstone for prevention and treatment of HO, once it has begun. This may maintain functional ROM of the joints even in the presence of HO and during the maturation of HO maturation⁶. Efficacy of diphosphonates, non steroidal anti-inflammatory medication (NSAIDs)⁷, radiotherapy and surgery is

debatable. Diphosphonates appear to be effective at inhibiting neurogenic HO in SCI and TBI patients and recurrence after resection of HO⁸. NSAIDs have not been shown to be effective in HO but seem to be effective in inhibiting recurrence in patients treated with surgical resection⁹. Prophylactic local radiotherapy has been used after hip surgery to prevent HO formation¹⁰. But it is not been tried in NHO. Surgical excision of HO is done on matured bone only when there is a loss of joint function or when other complications of the HO necessitate it.

In our patient we excluded possibility of myositis ossificans which usually follows following trauma and massage, muscle trauma by clinical examination and Rhabdomyolysis by urine examination for hematuria. Our patient had HO confined to both thighs with sparing of traditional sites viz. hip, knee and elbow. we excluded possibility of myositis ossificans which usually follows following trauma and massage, muscle trauma by clinical examination and rhabdomyolysis by urine examination for hematuria. Severe head injury, major surgery, prolonged vegetative state, hypertonia and systemic infections, which are the known risk factors during acute phase of TBI could have triggered HO in this patient. However, contribution of occult direct trauma to thighs at the time of head injury can not be excluded even though child was not having external evidence of abrasion, swelling or fracture. Timely and proper intervention facilitated recovery of range of motion of joints at knee.

Conclusion

Heterotopic ossification can rarely develop away from the joints in patients with TBI. Presence of multiple risk factors in severe TBI can predispose to HO. Awareness about this complication is essential for early diagnosis and management.

References

1. Garland DE. A clinical perspective on common forms of acquired heterotopic ossification. *Clin Orthop.*1991 Feb;263:13-29.
2. Buring K. on the origin of cells in heterotopic bone formation. *Clin Orthop.*1975 Jul-Aug;(110):293-301.
3. Taly AB, Nair KP, Kumar MV, Jayakumar PN, Vasudev MK, Ravishanker D, Kalaivani PL, Padankatty BS, Murali T. Heterotopic ossification in non-traumatic myelopathies. *Spinal cord.* 1999 Jan;37:47-9.
4. Baron, M, Stern, J, Lander P. Heterotopic ossification heralded by a knee effusion. *J.Rheumatol.* 1983 dec;10:961-4.
5. Buschbacher RM, Coplin B, Buschbacher LP, McKinley WO, Benign knee joint effusions in spinal cord injured and other paralysed patients: four case studies. *Am J. Phy med. Rehabil.* 1991Dec;70:309-12.
6. Stover SL Hataway CJ, Zieger HE. Heterotopic Ossification in spinal cord-injury patients. *Arch.Phys.Med.Rehabil.* 1975 May;56:199-204.
7. Ritter MA. Indomethacin: an adjunct to surgical excision of immature heterotopic bone formation in patient with severe head injury. A case report, *Orthopedics.* 1987 Oct;10:1379-81.
8. Garland DE, Blum CE, Water RL. Periarticular heterotopic ossification in head injured adults: Incidence and location. *J.Bone Joint Surg.* 1980 Oct;62:1143-6.
9. Mital MA, Garber JE, Stinson JT. Ectopic bone formation in children and adolescents with head injuries: its management. *J. Pediatr.Orthop.*1987 Jan-Feb;7:83-90.
10. Ayers DC, Evarts CM, Parkinson JR. The prevention of heterotopic ossification in high risk patients by low radiation after total hip arthroplasty. *J. Bone Jt. Surg.* 1986 Dec;68:1423-30.