

Splints in the Rehabilitation of Injured Hands

PROF. R. VENKATASWAMI, M.S., M.Ch., F.A.M.S., *Head of the Department of Plastic Surgery and Reconstructive Hand Surgery, Stanley Medical College & Hospital, Madras.*

The broad principles in the use of splints and their fabrication are discussed. The various types of splints used for the common problems in the hand are discussed in detail.

It is well known that splints are as important as surgery when the hand is concerned. Sometimes the splints do a better job than what surgery can offer.

The origin of word "Splint" is not exactly known. In 1946, Capner called the triangular segment of the armours surrounding the movable parts at the elbows, knees and ankles as splints. These splints afforded protection while still permitting movements.

The function of any splint is to maintain correct posture in a position of (1) rest; (2) realignment; (3) controlled activity.

The splints are broadly classified into three types:—

(a) **Static or passive splints**

The aims are:

1. To immobilise or limit the joint activity. The main aim here is to put the hand and wrist into a position of physiological rest and control, thereby limiting those movements which might be harmful to the process of healing.

2. To position and maintain correct joint alignment. A classical example is the use of static splint in correction of the claw deformity or the night splints used in the early stages of ulnar drift in rheumatoid hands.

3. To arrest the developing contractures. In a number of situations one gets the contractures as in shortening and fibrosis of paralysed muscles, shortening of joint capsules, diffuse fibrosis as a result of oedema, burns, etc.

In all these situations, static splints if used in the early stages can ward off the develop-

ment of contractures.

4. To maintain improvement obtained by Therapeutic passive stretching of contractures between treatments.

5. To stabilise and/or position one or more joints enabling other joints to function correctly. A classical example is the wrist cock up splint used to support the wrist in extension allowing the hand to grasp effectively.

(b) **Lively or dynamic splints**

This word lively was coined by Capner in early part of First World War. The aims are:

1. To prevent progressive deforming changes which can develop following segmental imbalance, e.g. preventing the development of claw hand in situations where it is likely to develop (Fig. 1).

2. To enable normal muscle to maintain

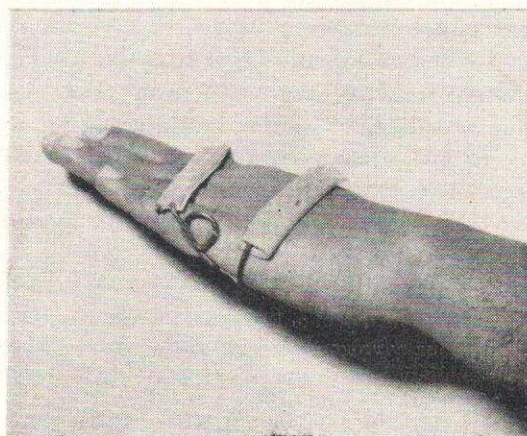


Fig. 1. Claw Correction Splint

power and tone, encouraging weak muscles to strengthen.

3. To correct the deformity caused by imbalance or paralysis while allowing normal muscle to maintain activity.

(c) Functional appliances designed for irreversible loss of function

They are meant for patients with profound loss of function as in congenital malformations, brachial plexus or spinal injuries. A number of new devices are available.

In the fabrication of the splints to the hand one should be careful in assessing the shape of the hand particularly the arches of the hand.

There are three planes for the hand. Two on the dorsum and one on the palm. These three constitute a triangle. The first and fifth metacarpals form the base and the index metacarpal the apex. In all positions of the hand the triangle remains although the shapes may be altered.

The three planes of the hand which form the triangle narrow towards the wrist and if these were continued they would meet as the apex of a pyramid.

Another feature to be taken into account is the fact that there is very little space in the palm, when all the fingers are brought into opposition with the thumb. This implies that any palmar bar or area of support should, as far as possible lie within this space, so as not to interfere with MP flexion and thumb rotation. The transverse arches of the hand formed distally by the metacarpal heads and proximally by the carpal bones are dynamic ones. They deepen as the finger tips come together. But on opening the hand the arches are flattened.

This dynamic nature is seen at work. The arch gets flattened when grasping a broom handle, spade or spanner. When holding tools of precision such as pen, small screw driver,

there is deepening of metacarpal arch as the finger tips come together.

Particular attention should be paid to the arc of motion of each finger. When the individual finger is flexed each tip points to the bony land mark of Trapezial ridge. In grip it will be noted that the terminal interphalangeal joints of the index, middle and ring fingers lie in close proximity to the thenar eminence with that of the little finger lying at its base. With the fingers in the position of the grip if a pencil is inserted through the fingers, one can observe the oblique angle of the pencil lying across the palm. This only shows that in making any splint which requires a band or bar across the palm this angle should be observed. When the fingers are relaxed with the pencil in same position it will be seen that there is a space between the centre of the palm and the pencil. However, if the pencil is pressed into the palm the arch will flatten. This will be the effect of palmar bar across the hand if it is not shaped to this arch. So care should be taken to shape the bar according to the arch.

Thus the following principles have to be kept in mind before fabricating the splints for the hand:

1. Any dorsal bar must angulate and be shaped to the curve of the dorsum.

2. If full range and arc of movement of fingers and thumb is maintained, any material or bar crossing the palm should not interfere with thumb rotation nor with the flexion of the MP joints.

3. Care should be taken to maintain the transverse metacarpal arch.

4. The palmar surface of the hand should have as little covering as possible so as not to interfere with sensation.

5. Forearm supports for static splinting should follow the physiological position of rest. In the construction of lively splints, forearm supports should allow for the longitudinal rotation function, wherever possible.

REQUIREMENTS OF A GOOD SPLINT

1. It should be as comfortable as possible. An adverse comment, made by the patient, should be respected and adjustments made, provided this does not interfere with the object of the splint.
2. Should be as simple as possible. Anything cumbersome and unsightly will be discarded by the patient.
3. The materials should be cosmetically acceptable to the patient.
4. Should avoid friction damage to the skin.

GENERAL PRECAUTIONS

1. *Circulation:* We should prevent circulatory disturbances by padding the points of pressure and distributing the pressure over an area as wide as possible.
2. *Timing:* No splint should be worn continuously for all the 24 hours. Initially it is removed frequently till, he feels comfortable. He must be given clear instructions regarding the period of time during which it should be worn.
3. *Skin Reactions:* Any redness or rashes should be noted which may be an indication that the material used, causes allergy.

SPLINTS USED FOR PREVENTION OF DEFORMITY

The most important area, where these splints are used, is in preventing the deformity, seen in peripheral nerve injuries. It is known that the paralysed muscles will be over stretched by the unopposed action of the antagonists if some form of splinting is not done. For example take the radial nerve palsy, the extensor muscles for the hand and forearm are paralysed. They are likely to be stretched if the wrist is not held in extension. Similarly in ulnar nerve palsy, the hyperextension of the MP joints of the ring and little finger tends to

stretch the capsular ligaments of these joints. In median nerve palsy, we do find the over action of the extensor pollicis longus, which is not opposed by the usual Opponens pollicis and abductor pollicis brevis. With the result, the thumb will be adducted and kept close to index finger and this will stretch the thenar muscles. In a combined median and ulnar palsy, the metacarpo-phalangeal joints of all the fingers would become hyperextended.

In preventing the deformity, the aim is not only to provide a static splint that will prevent or correct the deformity, but to provide a dynamic splint which will help in preventing deformity and also help in encouragement of function. Taking the example of radial nerve palsy, the splint which has been in use for a long number of years, is the cock up splints [Fig. 1] which Mr. Parry calls it as, "Dead

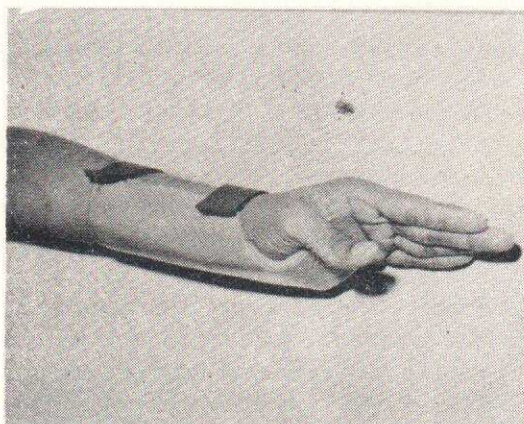


Fig. 1a. Static Cockup Splint

Splint". This does not allow any movement of the wrist. Instead if you can provide a lively splint [Fig. 2] that patient can actively flex the wrist and the splint tension will extend the wrist. This device can be easily constructed and is quite comfortable to wear. Patient do find that they attain good function and in many instances they can resume their normal work

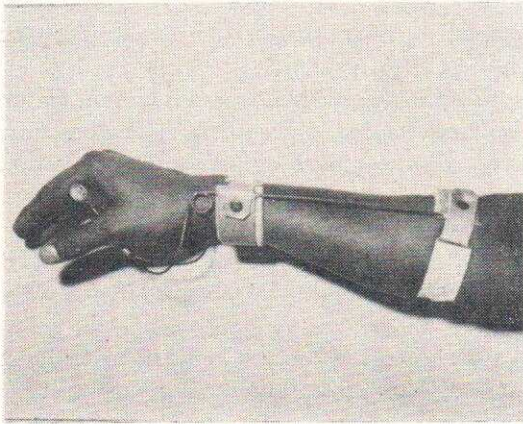


Fig. 2. Dynamic Cockup Splint




Fig. 4. Dynamic Knuckle Bender

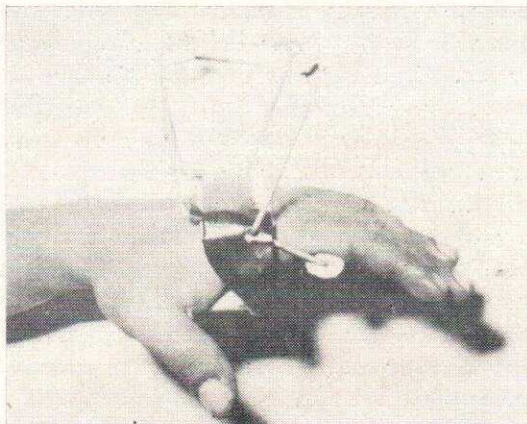


Fig. 3. Reverse Dynamic Knuckle Bender

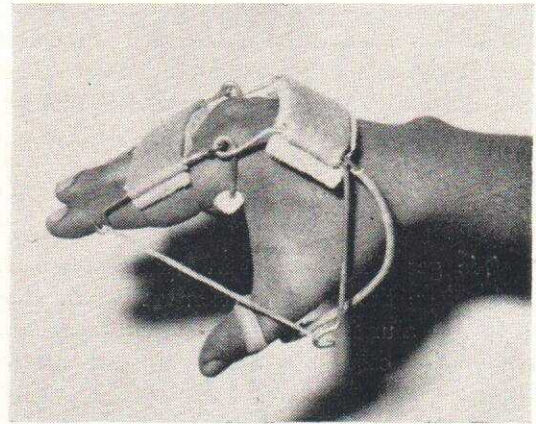


Fig. 5. Dynamic Knuckle Bender with outrigger

while wearing the splint. In cases where the extensors to the fingers alone are not acting, the reverse knuckle bender [Fig. 3] will be of great help. It keeps the fingers in extension and whenever the patient wants to flex the fingers he can do it. He can grip large objects easily. If both the wrist and finger extensors are paralysed this type of splint will be useful in keeping the wrist and IP joints of the fingers in extension.

Similarly for ulnar nerve lesions, a knuckle bender splint [Fig. 4] by which patient can

flex and extend the MP joints may be of use. The only disadvantage of using the rubber band is that it occupies space. It may not easily allow proper function of the hand. A static splint of this nature will prevent the deformity. But if a spring is added it will allow good function in addition.

For median nerve palsy a wrist band, to which a leather strap going around the thumb in an oblique manner, is used. This is convenient, but the wrist band has a disadvantage that it does slip and the position will be changing.

In cases where it is in association with the ulnar nerve palsy, a wire can be attached to the main knuckle bender and this can be adjusted in such a way that the thumb is kept in abduction and opposition [Fig. 5]. With this, the patient will be in a position to work and use the hand to the fullest possible limit. In a combined lesion, this form of splint will be very useful. Patient can carry on his work with the splint.

SPLINTS USED FOR CORRECTION OF DEFORMITIES

Mallet Deformities: This is common problem we meet with. Several types of splints are available. We use the simple aluminium strip cut to the size of the patient's finger and strap it with the adhesive. The needed extension at the DIP joint is given easily as the aluminium is malleable. Care is taken to see that the PIP joint is not involved.

BOUTENIERRE'S DEFORMITY

We get this problem in various stages. In early stage the passive extension is full. Here a simple aluminium strip or rubber tube is enough. In cases of established contracture of

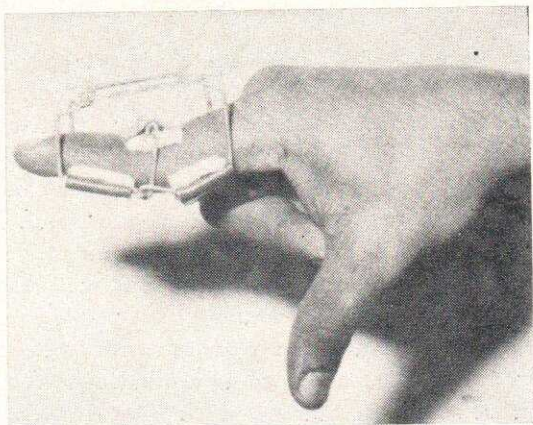


Fig. 6. Dynamic PIP Joint Extensor Assist Splint

the PIP joint, serial stretching with plaster may be needed. When this fails, dynamic finger extensor [Fig. 6] is used.

Stiffness of the joints, is a common feature following trauma, infection and tendon adhesions. All these lead to deformities of various kinds.

LIVELY SPLINTS USED TO CORRECT CONTRACTURES IN VARIOUS JOINTS

One should be very careful in using dynamic or lively splints in correcting such contractures. The dynamic splints may exceed the limit of force that is needed and this may cause minute ruptures of the tissues and this will lead to further scarring. So many, prefer serial stretching. Serial stretching has been popularised by Mr. Wynn Parry and others. We have also found it very useful.

In practice where serial stretching is needed intensive massages are given for about 10 minutes and then the deformity or the contracture is gradually stretched within the limits of tolerance and in this position plaster is applied and allowed to set. This is changed three or four times a day following each session of physical therapy and for use in nights, it is little under corrected and the plaster is applied. If this is continued, it is a pleasant surprise to see that majority of these contractures are stretched and the deformities corrected. It has got a very good application in case of tendon repair at various levels. If patients cannot stretch their fingers straight after about six weeks of physical therapy, passive stretches can be started. It gives very good improvement in function. So serial stretching is one of the important armamentarium in the hands of the orthotists to improve the function by correcting the fixed contractures.

The same principle can be applied for stiffness of the MP joints after crush injuries. Oil massage, stretches and serial plasters are success-

ful in these cases. It is important to mobilise the MP joints not only in flexion and extension, but also in rotation. This applies particularly to the Index finger when a cylinder grip is made. The inter-digital webs and the thumb web become fibrotic and same treatment plan is effective. The most useful way of maintaining correction of webs is by application of small plaster wedges which can be made easily and made to mould well to the deformities.

When it is not possible to have further improvement with serial stretching, dynamic splinting [Fig. 7] has to be brought into the

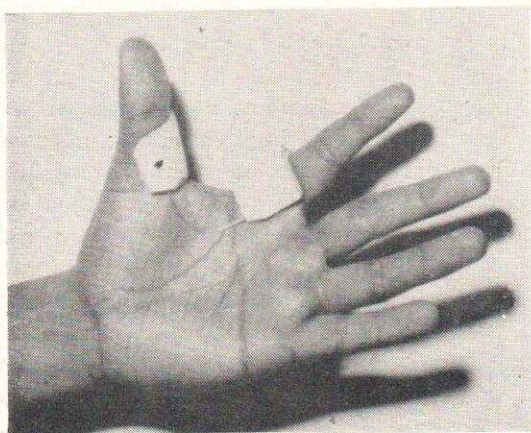


Fig. 1. Dynamic Thumb Web Spacer

picture. The tension of the coil spring can be gradually increased and made to give greater force. As mentioned earlier these devices act best on co-operative patients who are ready to accept them as active exercise and will work against the spring resistance. It is dangerous to use them in the early stage of treatment as they may promote further oedema and fibrosis. Only when fitted to the right patient at the right time, they can be most helpful in correcting the deformities.

MP Joints : When it is not possible to have flexion beyond 60 degrees, we use lively knuckle bender splints.

We may have to modify the knuckle bender splint, to suit the individual situations. Here is a case of flap cover to the dorsum of the hand. The flap should not be pressed by the dorsal aluminium strip of the splint. In this patient the support on the dorsum is taken more proximally and by the help of a joint, the dynamic flexion of the MP joints is achieved.

MP & IP Joints : Sometimes we have the flexion deformity of the IP joints in combination with collateral ligament contracture of MP joints. This is common after the flexor tendon repair or following severe crush injuries. In such situations, outrigger to each finger connected by a strap is given [Fig. 8]. The fulcrum here is on the proximal phalanges and the PIP joints are extended continuously by the dynamic traction of the rubber bands.

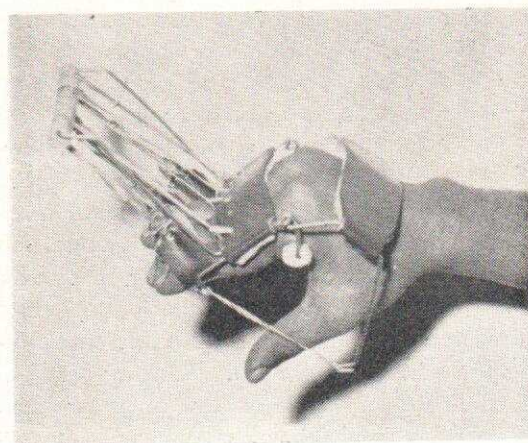


Fig. 8. Dynamic Knuckle Bender with Outrigger

IP Joints : The other lively splints are the inter-phalangeal extension and flexion splints. We do get the problem of PIP joint contracture either in flexion or in extension. In extension, we do encourage the flexion by this simple lively splint [Fig. 9] and it is very useful and gradually the deformity is corrected and if at any particular stage there is no improvement then there is an indication for surgery for this pro-

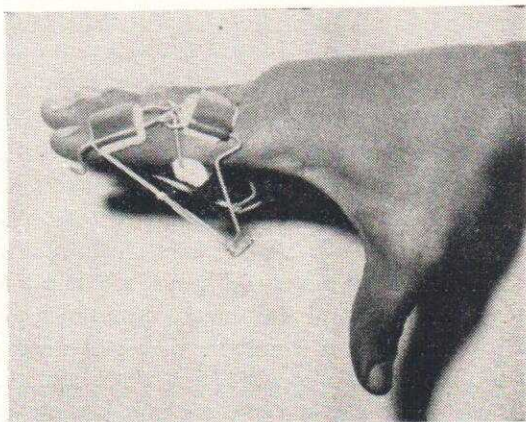


Fig. 9. Dynamic PIP Joint Flexor Assist Splint

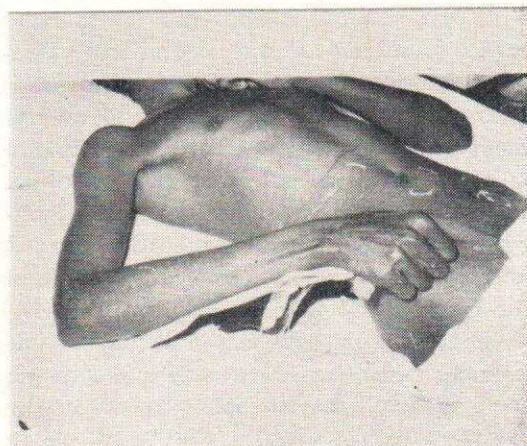

Fig. 10. Flap Supporting Splint

blem. For PIP joint contractures in flexion, the reverse of the same splint is applied to correct the flexion deformity and to have extension of the PIP joint [Fig. 6]. These splints are very easy to fabricate and can be given in about few hours time and it works very well.

Other splint which we found useful following flap attachment is flap supporting splint. The aim of this splint is to encourage the function in those areas unaffected by trauma. All of us who are engaged in providing skin cover to the hand and forearm in the form of flaps are quite aware of the difficulties in immobilising the hand and forearm. Kinking and undue pressure on the flaps have to be avoided. No doubt, a constant watch and vigil is essential in this type of flap surgery. But it is not possible or feasible to have such a continuous constant watch on these cases. Over the years we have been finding it is a problem and sometimes it is quite distressing to see good flaps

getting kinked. In addition, the patient does not use the unaffected fingers resulting in gross stiffness of the joints of these fingers. The rehabilitation team was stimulated to think on these lines and with the result we have evolved two or three splints [Fig. 10].

It is a simple one made of aluminium. It has two components as you see here. A basal plate horizontal in disposition. This part rests on the bed. The other oblique component is connected to the horizontal one by an adjustable support. This supports the forearm and hand which are strapped into position. This basic splint is adjusted to suit the various situations. For cases where only the thumb is lost and a flap is attached to the region of the thenar area, this type of splint is useful. It keeps the forearm and hand away from the trunk and it does not allow the wrist to drop. The remaining fingers are allowed to do exercises freely without disturbing the flap.